Enhancing wound healing after breast cancer with portable Negative Pressure Wound Therapy

KEY WORDS
- Breast cancer
- Mastectomy
- Portable Negative Pressure Wound Therapy
- Wound healing

Having a mastectomy for breast cancer is stressful in itself without then developing a wound infection and wound breakdown. Particularly, as this may result in a delay in vital chemotherapy treatment, which usually will not commence until the mastectomy wound has healed. This case study of a 53-year-old lady describes the use of portable, single-use Negative Pressure Wound Therapy (NPWT) to aid fast wound healing following mastectomy wound breakdown. The use of this type of portable NPWT enabled the patient to be managed as an outpatient and resulted in a rapid reduction in wound size and exudate level, and promoted healing.

JACKIE ROSS
Tissue Viability Clinical Nurse Specialist, Royal Berkshire NHS Foundation Trust, Reading

Breast cancer was the cause of death for nearly 11,500 people in the UK in 2014 (Cancer Research UK, 2016). It is the most common cancer amongst women (Office for National Statistics, 2016). Approximately 18,000 mastectomies for breast cancer are performed each year in England. These may be followed by other treatments such as radiotherapy and/or chemotherapy. Chemotherapy will not usually be commenced until the mastectomy wound has healed. This is due to the increased risk of further wound healing problems.

Hashemi et al (2004) identified seroma formation as the most common wound complication after surgery for breast cancer. They suggested that the risk was increased if the patient had had excision of the axilla lymph nodes. The incidence of seroma formation is reported by Boostrom et al (2009) as being between 3%–85%.

Case studies have shown that the use of negative pressure wound therapy (NPWT) can contribute to effective exudate management and positive healing outcomes in patients following wound infection and breakdown after breast surgery (Leak et al, 2009; Tottle and Harris, 2014). NPWT stimulates cell generation, encourages the formation of granulation tissue, contracts wound edges and reduces oedema (Green, 2012; Karlakki et al, 2013; Malmsjo et al, 2014).

This case study involves a 53-year-old lady who had a right mastectomy and axillary node clearance for breast cancer, and subsequently developed an infected seroma. The seroma was initially treated with antibiotic therapy. However, the infection failed to respond to the antibiotics and 7 weeks after the mastectomy, the patient underwent incision and drainage of a large multiloculated seroma with insertion of a corrugated drain.

The corrugated drain and the subcutaneous and deep sutures were removed at her GP practice 4 days post-surgery. The patient was then seen by the surgeon 5 days later and when the patient was examined, she was found to have a 9 cm long open wound (approximately 3 cm depth). The surgeon was concerned as the patient had been due to start chemotherapy but this was delayed due to the wound breakdown. The surgeon wrote to the GP stating that it appeared that the wound had reopened due to the removal of the suture and a copy of the letter was sent to the patient. The patient was then referred to the tissue viability service.

It was now 10 weeks since the initial surgery and there was a need to potentiate rapid wound healing in order for this patient to be able to undergo chemotherapy.

PAST MEDICAL HISTORY

The patient's past medical history included:

- Body Mass Index (BMI) which was 59 (weight 154.9 kg) when gastric band surgery was performed 2 years prior to the mastectomy. The patient had lost weight, so at the time of breast surgery, her BMI was 43.8 (weight 115 kg)
- Obstructive sleep apnoea, balloon valvotomy for pulmonary valve stenosis (8 years previously) and hypertension.

RATIONALE FOR USING NPWT

The decision to use NPWT was reached after assessing the wound, considering the patient, the aim of treatment and the management options available.

The patient was being treated as an outpatient and would be travelling approximately 20 miles to the hospital for dressing changes rather than to her GP surgery. The patient was reluctant to be treated at her surgery following the previous incident when the deep sutures and drain were removed. The amount of exudate from the wound was estimated to be less than 300 mls per week.

Therefore, a regimen where frequent dressing changes were not required, which would be discrete for the patient, allow her to maintain independence and promote rapid wound healing was chosen.

METHOD

A dressing regimen using PICO®, a portable single-use NPWT device, was applied over a 5-week period in an outpatient setting. Dressings were initially changed twice weekly, then 3 weeks after commencing NPWT. This reduced to weekly, as the wound size diminished and exudate levels reduced. Wound healing progress was monitored using measurements and photographs.

A non-adherent silicone contact layer was used on the wound bed and an antimicrobial gauze dressing was used to fill the cavity. The surrounding skin was protected using a barrier film lollipop, this also aided dressing adhesion.

Sealing the dressing was quite challenging near the axilla area due to moisture, hair and exudate tending to gravitate to that area. The patient's husband, who attended the appointments, was shown how to reseal the dressing edges if they lifted between dressing changes. The patient and her husband were given both verbal and written documentation about this type of portable NPWT device that included advice on showering and who to contact if they had any concerns.

Figure 1. 1 week after commencing NPWT

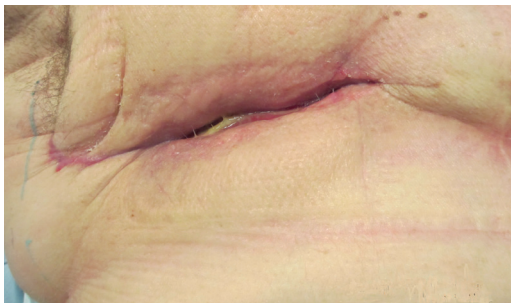

Figure 2. 2 weeks after commencing NPWT

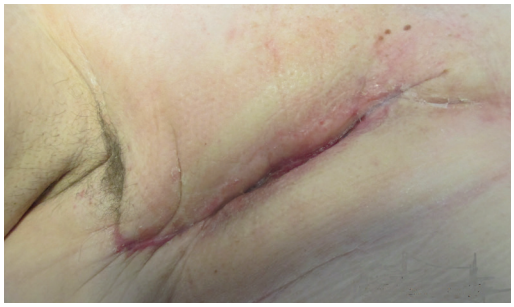

Figure 3. 3 weeks after commencing NPWT

RESULTS

At the initial application of the NPWT, the wound was 9cm in length x 3cm width and approximately 3cm depth. The wound edges were rolled and the wound bed was wet and red with some soft slough.

Within the first 2 weeks after commencing NPWT, the wound depth and width rapidly decreased in size, although there was still some soft slough present (*Figures 1* and *2*).

Three weeks after starting the dressing regimen there was a significant decrease in the size of the wound and amount of exudate. The wound had

decreased by 2.5 cm in length and 1.5 cm in depth. The wound bed had new granulation tissue covering approximately 90% of the wound bed (*Figure 3*).

The patient reported a decrease in oedema of the surrounding tissues, that she was able to lift her arm higher and that it was easier to complete her physiotherapy exercises. Her mood had noticeably improved and she and her husband were outwardly more positive.

After 5 weeks, the PICO dressing was removed as the wound bed was now at the level of the surrounding skin and the exudate level was greatly reduced.

POST-NPWT WOUND HEALING

After the intial rapid reduction in wound size and depth using the NPWT, the wound continued to reduce in size. However, the rate of healing then slowed and, at dressing removal, there was some moisture damage on the surrounding skin (*Figure 4*).

Ten weeks after commencing NPWT, the patient reported increased swelling of the tissues surrounding the incision wound and a feeling of heaviness in the area. There was no evidence of cellulitis or an increase in exudate level and the patient felt well (*Figure 5*).

The surgeon examined this area of swelling and felt it was not related to the wound and was breast-cancer-related lymphoedema. The patient was referred to a lymphoedema nurse specialist. The lymphoedema resulted in the wound being in a fold in the skin and the area tended to be moist. The moisture was resolved by the use of a different foam dressing.

The wound had almost healed 15 weeks after commencing NPWT (*Figure 6*) and was completely healed at 16 weeks, which was 26 weeks after the initial mastectomy operation. The patient was then reviewed in clinic by the Oncology Consultant with a view to commencing chemotherapy.

DISCUSSION

Wound infection and breakdown following mastectomy for breast cancer can have a devastating impact on a women's psychological health and body image (O'Regan, 2007), as well as potentially delaying lifesaving treatment.

Figure 4. 7 weeks after commencing NPWT

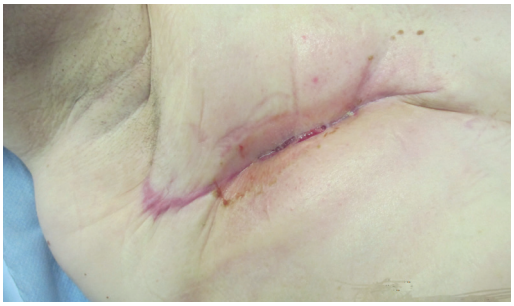

Figure 5. 10 weeks after commencing NPWT

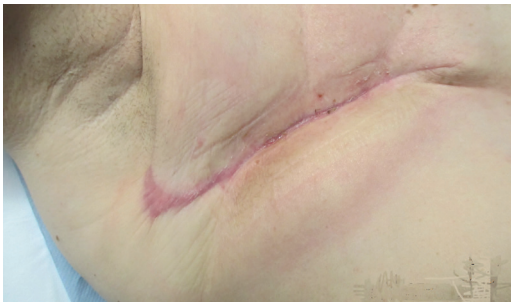

Figure 6. 15 weeks after commencing

Tanner et al (2011) identified that of 159 women who had primary breast surgery, 10.1% (16 patients) developed a surgical site infection (SSI). This is an unacceptably high level. However, this is a small study in one Trust and as the surveillance of SSI rates following mastectomy is not mandatory, there is no accurate nationwide data.

The patient in this case study had a high BMI and hypertension, which are risk factors for wound infection and breakdown. In a study by Derzie et al (2000), 15% of patients undergoing gastric band surgery were found to have suffered wound-related complications including seroma formation and dehiscence. Surgical wounds are more likely to break down in patients with a high BMI due to the force exerted at the wound edges when the wound is closed (Hahler, 2006).

Currently, portable NPWT is not used routinely for mastectomy incision management in patients with identified risk factors and generally used once a patient has a wound infection and/or wound breakdown.

However, there is a growing body of evidence for this type of incision management; Stannard et al (2009) proposed a risk factor grading system and their results indicated that NPWT applied immediately post-operatively might benefit at-risk patients. Also, an evaluation of NPWT used for women with a BMI >35 at 1 week post-caesarean showed the treatment reduced infection rates by 50% (Bullough et al, 2014). More studies are due to be published in 2017 (World Union of Wound Healing Societies [WUWHS], 2016).

Single-use, portable NPWT provides a treatment option with all the benefits of a canister-based system, including reducing the number of dressing changes, promoting wound healing and improving patient wellbeing (Hurd, 2014); combined with the added advantages of being able to treat patients in outpatient settings and promoting the patient's independence.

CONCLUSION

The treatment goal for this patient was for wound healing to have taken place prior to the commencement of chemotherapy within a short time frame. The treatment also needed to be small enough for the patient to manage at home and be comfortable and discreet.

Using single-use, portable NPWT met these needs and had a positive impact on the patient's experience and confidence that had been undermined by the diagnosis of breast cancer, mastectomy surgery and the subsequent wound infection that delayed healing.

The use of a portable, single-use NPWT device in this case accelerated wound healing. However, the need to use NPWT to treat a dehisced wounds following breast surgery could be reduced in the future, by using NPWT prophylactically on the incision immediately postoperatively, in patients at risk of wound complications. WUK

REFERENCES

Boostrom SY, Throckmorton AD, Boughey JC et al (2009) Incidence of clinically significant seroma after breast and axillary surgery. *J Am Coll Surg* 208(1): 148–50

Bullough L, Wilkinson D, Burns S, Wan L (2014) Changing wound care protocols to reduce caesarean section infection and readmission. *Wounds UK* 10(1): 72–6

Cancer Research UK (2016) *Breast Cancer Statistics.* Available at: http://www.cancerresearchuk.org/health-professional/cancer-statistics/statistics-by-cancer-type/breast-cancer (accessed 16.02.2017)

Derzie AJ, Silvestri F, Liriano E, Benotti P (2000) Wound closure technique and acute wound complications in gastric bypass surgery for morbid obesity: a prospective, randomized trial. *J Am Coll Surg* 191(3): 238–43

Green B (2012) Taking a closer look at what we understand about Negative Pressure Wound Therapy. *Prof Nurs Today* 16(4): 22–6

Hahler B (2006) An overview of dermatological conditions commonly associated with the patient with obesity. *Ostomy Wound Manage* 52(6): 34–47

Hurd T, Trueman P, Rossington A (2014) Use of a portable, single-use negative pressure wound therapy device in home care patients with low to moderately exuding wounds: a case series. *Ostomy Wound Manage* 60(3): 30–6

Karlakki S, Brem M, Giannini S et al (2013) Negative pressure wound therapy for management of the surgical incision in orthopaedic surgery. *Bone Joint Res* 2(12): 276–84

Leak K, Spruce P, Johnson S (2009) Improving outcomes for patients following surgery for breast cancer. *Wounds UK* 5(3): 47–55

Malmsjö M, Huddleston E, Martin R (2014) Biological effects of a disposable, canisterless negative pressure wound therapy system. *ePlasty* 14: e15

Office for National Statistics (2016) *Breast Cancer Statistics.* Available onlineat:https://www.ons.gov.uk/peoplepopulationandcommunity/healthandsocialcare/conditionsanddiseases/adhocs/004918breastcancerstatistics (accessed 16.02.2017)

O'Regan P (2007)The impact of cancer and its treatment on wound healing. *Wounds UK* 3(2): 87–95

Stannard JP et al (2009) Use of negative pressure therapy on closed surgical incisions: a case series. *Ostomy Wound Manage* 55(8): 58–66

Tanner J et al (2011) The rate, risk factors and cost of surgical site infections in primary breast surgery. *Journal of Infection Prevention* 12(5): 204–9

Tottle A, Harris S (2014) The use of negative pressure wound therapy in a non-healing breast wound. *Wound Practice & Research* 22(3): 142–4

World Union of Wound Healing Societies (2016) *Consensus Document. Closed Surgical Incision Management: Understanding the Role of NPWT.* Available at: http://www.wuwhs2016.com/files/WUWHS_SI_consensus_Web.pdf (accessed 16.02.2017)