Negative pressure wound therapy for sternal wound infections following congenital heart surgery

• **Objective:** This study examines the efficacy of a comprehensive, multidisciplinary wound management team and negative pressure wound therapy (NPWT) for the treatment of sternal wound infections in congenital heart surgery patients.

• **Method:** A single-institution retrospective review of all congenital heart surgery patients with post-operative sternal wound infections who were treated with NPWT was performed. Patients were evaluated based on (a) whether NPWT occurred before or after the establishment of a multidisciplinary wound management team, and (b) whether NPWT was initiated early (within 2 days) or late (greater than 2 days) after diagnosis of a sternal wound infection.

• **Results:** The median duration of NPWT was 12 days (range 2–50 days). NPWT was successfully initiated in patients as young as 15 days of age. There was a trend toward shorter duration of both NPWT and antibiotic use following (a) the implementation of the multidisciplinary wound management team, and (b) in patients with early use of NPWT; however, these results did not achieve statistical significance.

• **Conclusion:** NPWT can be successfully utilised in congenital heart surgery patients, including young neonates, for the treatment of sternal wound infections. The trends observed in the reduction of wound therapy duration and antibiotic duration with early implementation of negative pressure therapy and multidisciplinary wound management require further investigation to verify their clinical efficacy in patient care.

• **Declaration of interest:** There were no external sources of funding for this study. The author has no conflicts of interest to declare.

negative pressure wound therapy; sternal wound infection; congenital heart surgery; mediastinitis

Median sternotomy remains the standard incision when performing cardiac surgery for a variety of indications. Unfortunately, despite multiple advances in surgical technique and a general reduction in the incidence of infection, sternal wound infections (SWI) continue to be significant concerns following this surgical approach, with mediastinitis remaining a potentially life-threatening complication. Though uncommon, mediastinitis carries a high mortality rate and high associated morbidity.

In order to better address SWIs at our center, a Multidisciplinary Cardiac Surgical Wound Management Team (MCSWM) was created in July 2008. This team was established with the goal of lowering associated morbidity and mortality from cardiac surgical wounds through standardised, protocol-based wound care, chlorhexidine gluconate baths, antibiotic usage, and careful monitoring of infections by a combination of treating surgeons, infectious disease specialists, and certified wound advanced practice nurses. The MCSWM team meets on a daily basis to discuss the care of all patients with diagnosed and suspected SWIs. This enables the MCSWM team to create patient-specific plans in order to optimise the clinical care of each patient. This study was established to better understand the impact that this team has had over time and to specifically evaluate the efficacy of negative pressure wound therapy (NPWT) for post-sternotomy wound infections within our congenital heart surgery (CHS) population.

Method

This study was approved by the Institutional Review Board of Children's National Medical Center in Washington, DC. Our own internal database was assessed to identify paediatric patients (<18 years of age) who had undergone CHS and subsequently developed an SWI between January 2005 and December 2012. From this group, patients who were treated with NPWT were identified, and these individuals constituted the final patient cohort. In total, 30 patients met these inclusion criteria for review. These patients were divided into two groups. Patients in group 1 were admitted before the initiation of the MCSWM team (prior to July 1, 2008), and patients in group 2 were admitted after implementation of the MCSWM team. A second analysis was then undertaken where patients were further divided into two groups; those with early initiation

J.P. Costello,[1,2] MD; **J.K. Amling,**[3] RN, MSN; **D.A. Emerson,**[1] MD; **S.M. Peer,**[1] MD; **D.K. Afflu,**[1] BS; **D. Zurakowski,**[4] PhD; **R.A. Jonas,**[1] MD; **D.S. Nath,**[1] MD;
1 Division of Cardiovascular Surgery, Children's National Health System, Washington DC, US; 2 The Sheikh Zayed Institute for Pediatric Surgical Innovation, Children's National Health System, Washington DC, US; 3 Wound and Surgical Airway Program, Children's National Health System, Washington DC, US; 4 Departments of Anaesthesia and Surgery, Boston Children's Hospital, Harvard Medical School, Boston, MA, US.
Email: dnath@childrensnational.org

Table 1. Comparison of patient factors and outcomes based on period before and after implementation of comprehensive wound management team

Variable	1/2005 – 6/2008 (n = 17)	7/2008 – 12/2012 (n = 13)	p value
RACHS-1 Score	3 (2 – 6)	3 (2 – 6)	0.68
Aristotle Complexity Score	9 (6.3 – 14.5)	9 (6.3 – 14.5)	0.97
†In-hospital mortality	2 (12%)	1 (8%)	1.00
NPWT completed within 14 days of initiation	9 (53%)	9 (69%)	0.47
†Duration of NPWT, days	15 (2 – 30)	11 (3 – 50)	0.87
†Antibiotic therapy, days	25 (0 – 55)	17 (3 – 53)	0.62
Procedure			**0.44**
Primary sternotomy	10 (59%)	10 (77%)	
Redo sternotomy	7 (41%)	3 (23%)	
Delayed sternal closure	6 (35%)	5 (38%)	1.00
Severity of SWI			**0.72**
Superficial	12 (71%)	10 (77%)	
Deep	2 (12%)	2 (15%)	
Mediastinitis	3 (17%)	1 (8%)	
Prior hospitalization	12 (71%)	9 (69%)	1.00
Type of repair			**1.00**
Uni-ventricular	10 (59%)	8 (62%)	
Bi-ventricular	7 (41%)	5 (38%)	

† Primary end points. Scores and duration of NPWT and antibiotic therapy expressed as median (range).

Table 2. Comparison based on duration between identification of SWI and initiation of NPWT following CHS

Variable	Early initiation of NPWT (n = 16)	Late initiation of NPWT (n = 14)	p value
†In-hospital mortality	2 (13%)	1 (7%)	1.00
NPWT completed within 14 days of initiation	10 (63%)	8 (57%)	1.00
†Duration of NPWT, days	9 (2 – 50)	15 (6 – 45)	0.09
†Antibiotic therapy, days	17 (0 – 55)	26 (3 – 53)	0.40
Procedure			**0.71**
Primary sternotomy	10 (63%)	10 (71%)	
Redo sternotomy	6 (37%)	4 (29%)	
Delayed sternal closure	5 (31%)	6 (43%)	0.71
Severity of SWI			**0.65**
Superficial	**11** (69%)	11 (79%)	
Deep	**2** (12%)	2 (14%)	
Mediastinitis	3 (19%)	1 (7%)	
Prior hospitalization	**9** (56%)	12 (86%)	0.12
Type of repair			**0.28**
Uni-ventricular	**8** (50%)	10 (71%)	
Bi-ventricular	8 (50%)	4 (29%)	

† Primary end points. Duration of NPWT and antibiotic therapy expressed as median (range).

of NPWT (0-2 days) after identification of an SWI, and those with late initiation of NPWT (>2 days) after identification of an SWI. All NPWT was delivered using the Vacuum Assisted Closure (V.A.C.®, Kinetic Concepts, Inc., San Antonio, Texas) system (our institution currently utilises the V.A.C.Ulta™ device for all inpatients). NPWT was used exclusively on open wounds which were healing by secondary intention (NPWT was not utilised on any closed sternal incisions).

Prior to the establishment of the MCSWM team in July 2008, the identification and treatment of sternal wounds at our institution was accomplished by various care providers, including the treating surgeon and certified wound advanced practice nurses. The coordination among these providers, however, was not formally organised and did not constitute a true multidisciplinary team approach. As such, there was not a standardised method to the diagnosis of SWIs or the initiation of NPWT, except as determined by these individual care providers. After July 1, 2008, a more comprehensive assessment of all sternal wounds was conducted by the MCSWM team prior to the diagnosis of an SWI or the initiation of NPWT. All SWIs adhered to the criteria set forth by the U.S. Centers for Disease Control and Prevention (CDC).[1] SWIs were diagnosed based on the presence of specific clinical signs, including: erythema, purulent drainage, elevated white blood cell count, positive microbial cultures, fever, and other clinical signs of infection. Initiation of NPWT was at the discretion of the MCSWM team. In addition, all SWIs underwent risk control assessments to help determine the cause(s) of the infections and make recommendations for care improvement methods.

Statistics

Statistical analysis was performed using IBM® SPSS® Statistics (version 21.0, IBM®, Armonk, NY). $p<0.05$ (95% confidence level) was considered statistically significant. Univariate analysis was performed using the Mann-Whitney U-test for con-

Fig 1. Age at initiation of NPWT

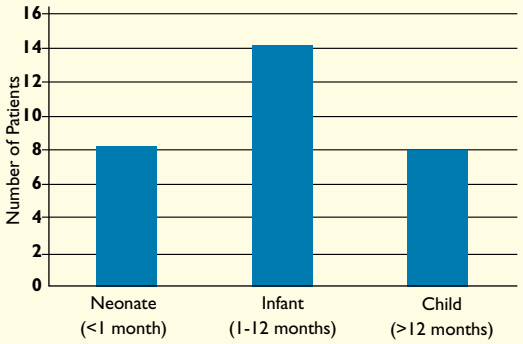

tinuous variables. Fisher's exact test for proportions was used for comparing patients before and after July 1, 2008, as well as patients who had initiation of NPWT ≤2 days or >2 days following SWI diagnosis. Length of antibiotic therapy and duration of NPWT were evaluated using median and range.

Results

Between January 2005 and December 2012, 30 CHS patients were treated with NPWT for SWIs at our institution. There were a total of 3 deaths (in-hospital mortality of 10%). The patient cohort was used to conduct two distinct analyses: 1) a comparison of patients pre- and post-implementation of the MCSWM team in July 2008 (Table 1), and 2) a comparison of patients where NPWT was implemented ≤2 days or >2 days following diagnosis of an SWI (Table 2). The primary endpoints considered in this study were duration of NPWT, length of antibiotic therapy, and in-hospital mortality. To ensure similarity between study groups, Risk Adjustment in Congenital Heart Surgery (RACHS) and Aristotle scores were analysed for all patients.

The study population was comprised of 17 female (57%) and 13 male (43%) patients, with a median age at surgery of 45 days (range 2–856 days). Median RACHS and Aristotle scores were 3 and 9, respectively, for both time periods (p=0.68, p=0.97) indicating similarly complex surgical populations. Patients underwent both univentricular (n=18) and biventricular (n=12) surgical repair, including Fontan procedure (n=7), stage 1 Norwood procedure (n=5), tetralogy of Fallot (TOF) repair (n=4), total anomalous pulmonary venous return (TAPVR) repair (n=3), modified Blalock-Taussig shunt (n=3), and complete atrioventricular canal repair (n=3). Based on the CDC classification of surgical wound infections, the SWIs were found to be superficial in 22 patients (73%), deep in 4 patients (13%), and true mediastinitis in 4 patients (13%).[1] Patients were treated with broad-spectrum intravenous antibiotics, consisting of vancomycin and at least one other antibiotic, most commonly piperacillin/tazobactam, gentamycin, or meropenem. Mediastinal microbial cultures revealed that most sternal wounds were populated with *Staphylococcus aureus* (n=8), coagulase-negative staphylococci (n=5), and *Enterococcus faecalis* (n=2).

NPWT settings ranged between -25 and -125 mmHg of suction. The median duration of NPWT for all patients was 12 days (range 2–50 days). The median number of days between each NPWT dressing change for all patients was 3 days. Overall, the median number of dressing changes throughout the entire course of NPWT was 3 dressing changes (range 1–13 dressing changes). NPWT duration was less than 14 days in 18 patients (60%). The duration of NPWT tended to be shorter following the creation of the MCSWM team and longer for patients with late implementation of NPWT though these findings were not statistically significant. In addition, there was a trend toward shorter duration of antibiotic therapy following creation of the MCSWM team and in patients with early implementation of NPWT (17 versus 25 days, and 17 versus 26 days, respectively) though these results did not achieve statistical significance. The median length of hospitalisation was 41 days (range 7-166 days). There were no cases of sternal wound reinfection in the study population.

Fig 2. The use of NPWT for an SWI in a CHS patient

Discussion

In this study, several important trends were identified related to the overall duration of NPWT and antibiotic therapy in CHS patients with SWIs. With early implementation of NPWT (≤2 days after identification of infection), there was a trend toward reduced duration of NPWT and a reduction in antibiotic days compared to late implementation of NPWT. Though these findings did not achieve statistical significance due to low power, they do suggest that beginning NPWT earlier may reduce the need for further intervention, likely by preventing progression of infection within the wound. A second similar trend was also observed in patients treated after the establishment of our comprehensive wound management team. With this team in place, there was a trend toward a reduction in length of NPWT and duration of antibiotic use compared to prior to our multidisciplinary wound management approach, although these findings did not reach significance.

References

1 Mangram, A.J., Horan, T.C., Pearson, M.L., et al. Guideline for prevention of surgical site infection, 1999. Hospital Infection Control Practices Advisory Committee. Infect Control Hosp Epidemio 1999; 20: 4, 250–278.

2 Al-Sehly, A.A., Robinson, J.L., Lee, B.E. et al. Pediatric poststernotomy mediastinitis. Ann Thorac Surg 2005; 80: 6, 2314-2320.

3 Garner, J.S., Jarvis, W.R., Emori, T.G. et al. CDC definitions for nosocomial infections, 1988. Am J Infect Control 1988; 16: 3, 128-140.

4 El Oakley, R.M., Wright, J.E. Postoperative mediastinitis: classification and management. The Ann Thorac Surg 1996; 61: 1030–1036.

The criteria for diagnosis of an SWI vary from institution to institution as well as between individual clinicians. However, there have been attempts at standardisation of criteria and terminology, most notably by the CDC. SWIs can be classified as superficial, deep, or organ space (sternal osteomyelitis or mediastinitis) infections.[1-3] A more detailed classification scheme developed by El Oakley and Wright may be used to further categorise mediastinitis.[4] Regardless of the criteria used, clinical differentiation and documentation of the true depth of infection remain challenging. Microbiological cultures of deep sternal wounds have shown colonisation by a wide variety of organisms, including: *Staphylococcus aureus* (both MSSA and MRSA), *Staphylococcus epidermidis*, coagulase-negative staphylococci, *Escherichia coli*, *Enterococcus sp.*, *Enterobacter sp.*, *Klebsiella pneumoniae*, *Pseudomonas aeruginosa*, *Proteus vulgaris*, *Corynebacterium sp.*, *Serratia marcescens* and *Acinetobacter baumannii*, with polymicrobial infections also being common.[5,6] This variety of potential organisms reinforces the importance of obtaining wound cultures and tailoring antibiotic therapy appropriately once susceptibility data are known. In both paediatric and adult populations, deep sternal wounds are most often colonised by *Staphylococcus aureus* and coagulase-negative staphylococci,[7,8] a finding that was also reflected in our data.

Though uncommon, the development of mediastinitis following median sternotomy for cardiac surgery remains a potentially devastating complication which may lead to the prolongation of in-hospital stay, increased costs, other morbidities, or mortality.[6,7] With the advent of more effective surgical techniques and antibiotic therapies, the incidence of deep SWIs is now an infrequent occurrence (currently reported at 0.2% to 5% in the adult cardiac population); however, the mortality rate remains high, at up to 35%.[6,7] Data suggest that the incidence of SWIs of all severities in the paediatric population is similar, at 0.2 to 4.8%.[2,9] However, there is an overall relative paucity of data regarding mediastinitis rates within the paediatric population.

Multiple studies have identified risk factors associated with the development of mediastinitis. In adults these include diabetes, obesity, chronic obstructive pulmonary disease (COPD), and renal failure.[5] Within the paediatric population, however, many of the classic risk factors do not apply. In this population, younger age, longer duration of surgical procedure, and higher American Society of Anesthesiologists (ASA) score have been identified as risk factors for mediastinitis.[2]

Traditional management of SWIs has included irrigation with antibiotic solutions, aggressive debridement, wound packing, delayed sternal closure, and complex reconstruction using vascularised muscle flaps. NPWT has been adopted in the management of SWIs as an adjunct to traditional management, with the goal of reducing the need for debridement and complex flaps.[6] Results with this technology have been encouraging,[10] and utilisation of NPWT in SWIs has become increasingly common. However, though there are a substantial number of publications demonstrating the efficacy of NPWT in the adult cardiac population,[7] very little data exist in the published literature regarding paediatric use.[11]

Fig 3. Healing of an SWI that occurred in an infant following CHS

A. Sternal wound at NPWT dressing change. **B.** Sternal wound following completion of NPWT

The established CDC criteria form the basis for our current approach to the management of SWIs. If a definitive diagnosis according to these criteria is made and the sternal wound is opened, we aggressively consider NPWT in all cases in an effort to 'jump start' granulation within the wound bed. Once the SWI is controlled and the wound appears to be granulating well, our team actively evaluates every wound for potential delayed primary closure versus continued healing by secondary intention, with frequent use of delayed primary closure once granulation tissue has reached the surface of the wound. As redo operations are often necessary in the CHS population, a secondary attempt at sternal wound closure should be undertaken in every patient with a SWI. This has been our preferred practice as our experience with NPWT in the management of SWIs has matured over the years. NPWT is conducted at different pressures depending on the age and clinical status of the patient. For neonates and infants the initial pressure is -25 to -50 mmHg, while for older children therapy is initiated at -50 mmHg. These pressures may be gradually increased up to a maximum of -125 mmHg starting as soon as day 1 after NPWT is initiated and once haemostasis is achieved. The initial negative pressure is started at lower, conservative values due to the concern of sternal instability and in order to minimise the risk of bleeding. It is important to note that the NPWT reported in this study is utilised on a very complex patient population, namely CHS patients, including small neonates (Fig 1–3), which is infrequently discussed in the medical literature.

5 Deniz, H., Gokaslan, G., Arslanoglu, Y. et al. Treatment outcomes of postoperative mediastinitis in cardiac surgery; negative pressure wound therapy versus conventional treatment. J Cardiothorac Surg 2012; 7: 67.

6 Fuchs, U., Zittermann, A., Stuettgen, B. et al. Clinical outcome of patients with deep sternal wound infection managed by vacuum-assisted closure compared to conventional therapy with open packing: a retrospective analysis. Ann Thorac Surg 2005;79:526-31.

7 Gustafsson, R., Johnsson, P., Algotsson, L., et al. Vacuum-assisted closure therapy guided by C-reactive protein level in patients with deep sternal wound infection. J Thorac Cardiovasc Surg 2002; 123: 5, 895–900.

8 Huddleston, C.B. Mediastinal wound infections following pediatric cardiac surgery. Semin Thorac Cardiovasc Surg 2004; 16: 1, 108–112.

9 Woodward, C.S., Son, M., Calhoon, J. Sternal wound infections in pediatric congenital cardiac surgery: a survey of incidence and preventative practice. The Ann Thorac Surg 2011; 91: 799–804.

In addition to improving wound healing, NPWT has several further benefits. By utilising NPWT, the need for ventilator support is reduced due to the stabilisation of the anterior thoracic wall by the negative pressure established with the NPWT system (while not concurrently impairing respiratory mechanics).[12] In the neonatal population, pain also appears to be improved with NPWT, with dressing changes often not requiring sedation in these patients.[13] The use of NPWT can result in fewer dressing changes and fewer invasive surgical procedures on the sternal wound (both at the bedside in the ICU and in the operating room), and deeper wounds can be healed in a shorter time frame. Patients can also be successfully discharged sooner as NPWT provides the option for home wound therapy outside of the hospital setting, thus reducing length and cost of hospitalisation. These additional benefits, along with the improved outcomes achieved when combined with traditional management options,[8,14,15] will foster continued development of this treatment modality as standard of care in CHS patients.

Conclusion

Though statistical significance was not achieved in this study due to the small size of the population examined, definitive trends exist that warrant further inquiry. We believe that the trends seen in reduction in duration of treatment with NPWT as well as duration of antibiotic therapy in the early (≤2 day) implementation group and after establishment of a comprehensive wound management team are true phenomena. These observations hold potential clinical significance in terms of reducing hospital costs, length of hospitalisation, and in-hospital mortality in CHS patients. Further study is needed to better confirm these trends and their true impact on clinical care. ■

10 Morykwas, M.J., Argenta, L.C., Shelton-Brown, E.I., McGuirt, W. Vacuum-assisted closure: a new method for wound control and treatment: animal studies and basic foundation. Ann Plast Surg 1997; 38: 6, 553–62.

11 Butter, A., Emran, M., Al-Jazaeri, A., Ouimet, A. Vacuum-assisted closure for wound management in the pediatric population. J Pediatr Surg 2006; 41: 5, 940–942.

12 Gustafsson, R., Sjogren, J., Malmsjo, M. Vacuum-assisted closure of the sternotomy wound: respiratory mechanics and ventilation. Plast Reconstr Surg 2006; 117: 4, 1167–1176.

13 Fleck, T., Simon, P., Burda, G. et al. Vacuum assisted closure therapy for the treatment of sternal wound infections in neonates and small infants. Interact Cardiovasc Thorac Surg 2006; 5: 3, 285–288.

14 Berg, L.T., Jaakkola, P. Kuopio treatment strategy after deep sternal wound infection. Scand J Surg 2013; 102: 1, 3–8.

15 Kadohama, T., Akasaka, N., Nagamine, A. Vacuum-assisted closure for pediatric post-sternotomy mediastinitis: are low negative pressures sufficient? Ann Thorac Surg 2008; 85: 3, 1094–1096.